

Successful Outcome of Therapeutic Hypothermia in A Case of Sudden Postnatal Cardiac Arrest and Asphyxia: A Case Report and Literature Review

Roychoudhury S¹,
Mohammad K¹, Yusuf K¹,
Obaid H² and Al-Awad E¹

- 1 Section of Neonatology, Department of Pediatrics, University of Calgary, Canada
- 2 Section of Pediatrics, Peter Lougheed Centre, University of Calgary, Canada

Abstract

Therapeutic hypothermia has become the standard of care for newborns with perinatal asphyxia, for long term neuroprotection. Though, definitive literature on role of therapeutic hypothermia in out of hospital cardiac arrests in pediatric population is limited. Furthermore, little is known about the role of therapeutic hypothermia in cases of sudden unexpected postnatal cardiac arrest and asphyxia. We report a case of a Preterm infant born at 35 weeks, with cardiac arrest soon after birth that was treated successfully with therapeutic hypothermia for 72 hours.

Keywords: Therapeutic hypothermia; Sudden Infant Death Syndrome (SIDS); Hypoxic-Ischemic Encephalopathy (HIE)

Received: April 18, 2017; **Accepted:** April 25, 2017; **Published:** April 30, 2017

Introduction

Therapeutic hypothermia has become the standard of care for newborns with perinatal asphyxia, for long term neuroprotection. Hypothermia has been a tried and tested strategy in neuroprotection in cardiopulmonary bypass surgeries in both adult and pediatric population. With trials incorporating therapeutic hypothermia in adults with out of hospital cardiac arrests [1], showing improved neurologic outcomes, international guidelines are strongly recommending use of the same in the comatose adults. Conclusive evidence on the role of therapeutic hypothermia in out of hospital cardiac arrests in pediatric population, though, is limited, but many observational studies have emphasised its growing relevance on the same [2]. Anecdotal reports too suggest that therapeutic hypothermia was a standard of care for drowning, and even Reye's syndrome prior to the turn of this century.

Little is known about the role of therapeutic hypothermia in cases of sudden unexpected postnatal cardiac arrest and asphyxia. Given the vulnerability of the infant brain to the excitotoxicity, therapeutic hypothermia may help attenuate the impact [2,3]. We report case of cardiac arrest soon after birth that was treated successfully with therapeutic hypothermia for 72 hours.

Corresponding author:

Dr. Essa Hamadan Al Awad

✉ essa.alawad@albertahealthservices.ca

Clinical Associate Professor, University of Calgary, Section of Neonatology, Peter Lougheed Centre, 3500, 26th Ave, NE, Calgary, AB T1Y6J4, Canada.

Tel: (403)943-4892

Fax: (403)943-2565

Citation: Roychoudhury S, Mohammad K, Yusuf K, et al. Successful Outcome of Therapeutic Hypothermia in A Case of Sudden Postnatal Cardiac Arrest and Asphyxia: A Case Report and Literature Review. J Pediatr Care. 2017, 3:2.

Case Presentation

A late preterm (35 + 5 weeks' gestation) male was found apneic, unresponsive with asystole at 10 minutes of age while cared skin to skin by the mother. The baby was born by Caesarean section at 35 + 5 weeks due to preterm labour and previous caesarean section with failure to progress. The mother was otherwise a healthy 36-year-old with unremarkable antenatal course, no history of recreational drugs, smoking or alcohol. Apgar scores were 4 and 8 at 1 and 5 minutes, respectively, with favorable cord gases (pH: 7.24, BE: -4). Baby required only brief positive pressure ventilation for the first minute of age, with subsequent successful transition to room air, he continued to do well, and skin to skin was initiated by 6 min of age.

The baby was found apneic, bradycardic at 10 minutes of age, cardiopulmonary resuscitation was immediately initiated, including Intermittent positive pressure ventilation (IPPV) followed by intubation after 5 minutes in view of no spontaneous

respiratory efforts. Chest compression was also undertaken after failure to establish circulation by 2 minutes of effective IPPV, eventually escalating to epinephrine (2 intravascular doses). Fluid resuscitation through emergent umbilical venous catheter was accomplished, and finally, Naloxone was administered, for possible maternal intrapartum morphine induced cardiorespiratory compromise. Chest compression was continued for 20 minutes for subsequent asystole. Baby was finally, stabilized by 45 minutes of age, with heart rate above 100. Investigations post stabilisation revealed severe metabolic acidosis (base excess of -23, with serum lactate of 11.8), but no hypoglycemia. Further investigations suggested severely deranged liver function, creatinine, and lactic acidosis. Troponin levels were also markedly elevated Laboratory investigations (Table 1). Patient was then transferred to level 3 neonatal intensive care unit for further management.

On physical examination post resuscitation and stabilisation, baby had decreased level of consciousness, no spontaneous movements, hypotonic, depressed primitive and deep tendons reflexes, consistent with moderate to severe encephalopathy (Sarnat stage II-III). Therapeutic hypothermia was initiated after discussion with parents, as there are no clear guidelines for therapeutic hypothermia for babies with postnatal asphyxia.

Table 1 Laboratory investigation on stabilization at 45 minutes of age.

Arterial Blood Gas	pH: 7.00
	PaCO ₂ : 29 mmHg
	PaO ₂ : 77 mmHg
	HCO ₃ ⁻ : 7 mmol/L
	BE: -23 mmol/L
Electrolytes	Lactate: 11.8 mmol/L
	Sodium: 138 mmol/L
	Potassium: 4 mmol/L
	Chloride: 107 mmol/L
	Calcium: 2.32mmol/L
CBC and Differentials	Ionized Calcium: 1.34 mmol/L
	Hemoglobin: 136 g/L
	HCT: 0.40 L/L
	RBC: 3.5 10 ¹² /L
	WBC: 16.6 10 ⁹ /L
	Neutrophil: 7.3 10 ⁹ /L
Renal Function Test	Band 0.7 10 ⁹ /L
	Platelet: 200 10 ⁹ /L
	Urea: 3.6 mmol/L
Liver Function Test	Creatinine: 62 umol/L
	Alanine transaminase: 15 U/L
	Gamma-glutamyl transferase: 177 U/L
	Alkaline phosphatase: 206 U/L
	Bilirubin: 38 ummol/L
	Prothrombin INR: 1.7
C- Reactive Protein	Partial thromboplastin time: 50.1 seconds
	Ammonia: 59 ummol/L
Creatine kinase (CK)	1.2 mg/L
Troponin T-High Sensitivity	5535 U/L
	12350 ng/L

Therapeutic hypothermia was continued for the next 72 hours without side effects. He was mechanically ventilated for 6 days and then successfully extubated to room air. During the initial course of stabilization, hypotension and severe lactic acidosis was managed by fluid resuscitation and inotropic support (Dopamine and Dobutamine). Inotropes were weaned off by day 3 of life. He was observed to be lethargic in the initial course, which gradually improved over the next 48 hours.

Initial working diagnosis were sudden infant death syndrome (SIDS), with differentials being airway obstruction, sepsis and inborn errors of metabolism. Detailed metabolic work up, including but not limited to serum ammonia, plasma and urine aminoacidogram, was undertaken in view of severe metabolic acidosis, all of which were normal. The metabolic acidosis and hyperlactatemia resolved in the next few days with adequate fluids and inotropic support. An electrocardiogram, to rule out long QT syndrome and an echocardiogram were performed, both of which were normal.

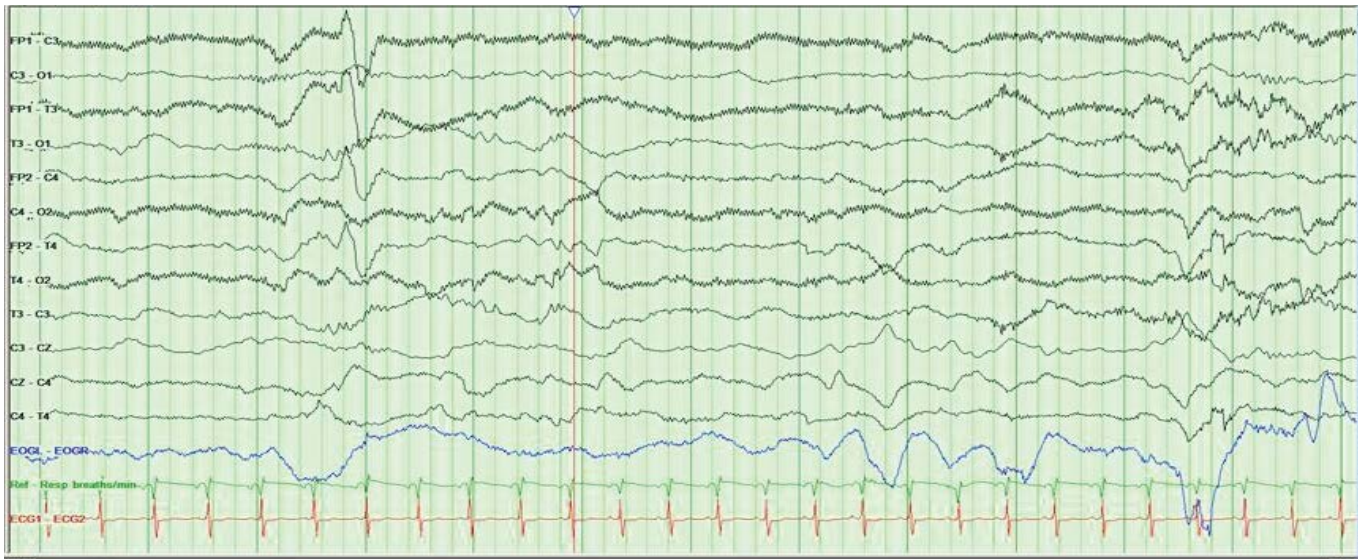
The patient's neurological condition showed progressive improvement in the next few days. By 5 days of life, he was alert, active with appropriate reflexes. Feed was initiated soon after extubation, and achieved full oral feeds by the end of the second week of life. An electroencephalogram and a Magnetic resonance imaging of brain were completed on day 3 and day 5, respectively, both of which were normal (Figures 1 and 2).

Given the above clinical scenario with the supportive investigation profile, the diagnosis was narrowed to possible Sudden Infant Death syndrome after excluding other differential diagnoses. He was discharged home around 18 days of life. Home monitoring was started for the next few months as per parental request, and subsequently discontinued at 6 months of age. The infant was followed closely at regular intervals at the Neonatal Follow up clinic and pediatrician for the neurodevelopment assessment. At 36 months of age, he was doing well, in preschool and achieved all his neurodevelopmental milestones appropriately.

Discussion

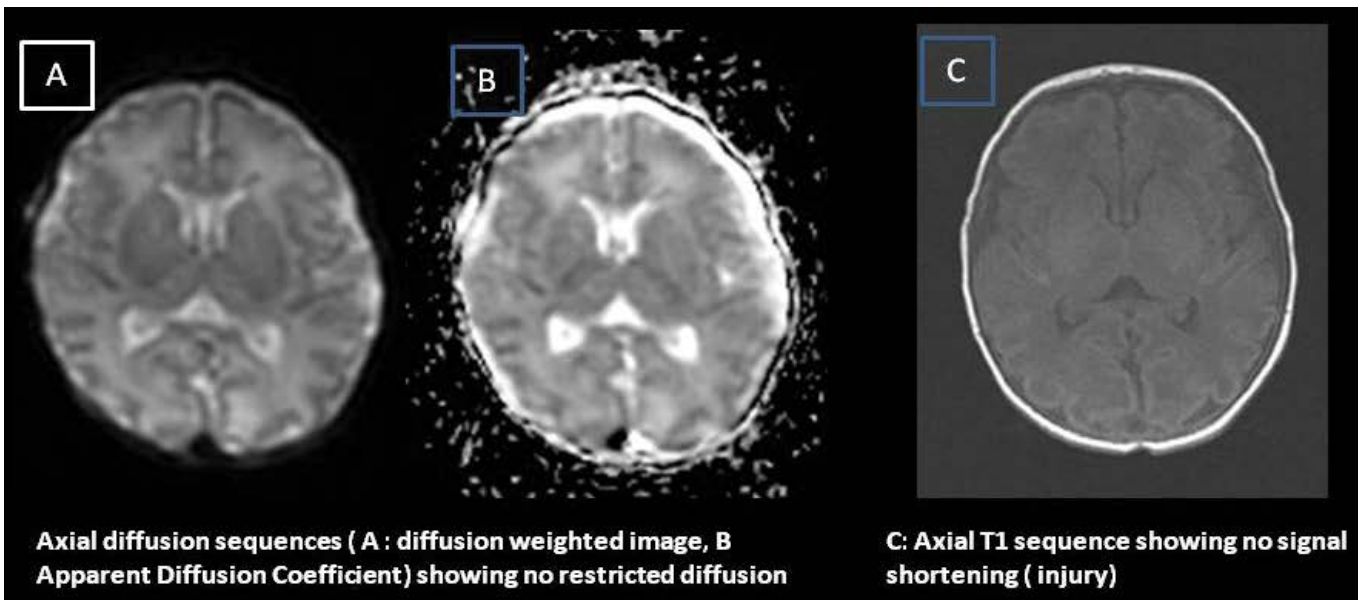
Sudden infant death syndrome (SIDS) remains the highest cause of death in neonates and infants. 5% of the unexpected deaths occur in the first postnatal week [4]. Sudden unexpected postnatal collapse is a subset of catastrophic events occurring within the first 24 hours of age. Though, sudden unexpected postnatal collapse is rare but can lead to devastating outcomes, in addition to, severe disability. These events have been found to occur with skin to skin and prone positions in more than three-quarters of the time [4-7].

The ultimate goal of resuscitation, across ages, is to preserve brain function. To this effect, therapeutic hypothermia has increasingly become the standard of care to prevent acute brain injury across all age groups and in diseases like traumatic brain injury, stroke, and near drowning. In fact, it has been found to be one of the most effective intervention to reduce neurologic injury and morbidity post cardiac arrest in adult population [8,9]. Mild hypothermia has also been found to be effective in aborting seizures in cases of refractory status epilepticus in



Snapshot of full montage EEG showing normal continuous background with no epileptiform activity or asymmetry

Figure 1 Full montage EEG on day 3 of life for our patient with normal finding.



Axial diffusion sequences (A : diffusion weighted image, B Apparent Diffusion Coefficient) showing no restricted diffusion

C: Axial T1 sequence showing no signal shortening (injury)

Figure 2 MRI of the brain done on day 5 of life with normal finding.

adults [10,11]. Therapeutic hypothermia has also, in the last few decades, consolidated its role in the management of post cardiac arrest and resuscitation of cold-water drowning of pediatric population [12]. Its role in perinatal asphyxia has revolutionised the management and outcomes in newborns. However little evidence is available about the effect therapeutic hypothermia may have on postnatal cardiac arrest after successful transition.

Injury secondary to encephalopathy post cardiac arrest in an otherwise healthy newborn, is not a single event occurring at the time of compromise, instead, it is an evolving process, just like others. It undergoes the ischemia- reperfusion phases, like the insult in a perinatal asphyxia, leading to energy failure, accumulation of excitatory neuro-transmitters, loss of membrane potentials leading to cytotoxic oedema, and then subsequent

deterioration secondary to free radical formation, induction of apoptosis and inflammatory cytokines. This secondary phase of injury occurs in the ensuing hours and persists for days, often as a result of, widespread apoptosis in the neuronal cells. Therapeutic hypothermia, if initiated, before the onset of this secondary phase of injury, reduces the apoptotic cell death [13,14].

Modest amount of hypothermia can generate a neuroprotective effect [15]. Several multicenter trials have proven benefits of therapeutic hypothermia in hypoxic ischemic encephalopathy in term neonates [16]. Mechanisms of therapeutic hypothermia are manifold. It reduces the cerebral metabolism, the accumulation of excitotoxic neurotransmitters and the generation of oxygen free radicals and inflammatory cytokines. Cerebral energy phosphates are preserved and cerebral alkalosis and lactate are reduced [17]. It also leads to the suppression of the apoptotic mechanisms at play, and inhibits the activation of the microglia.

Hence, it wouldn't be an exaggeration to say, therapeutic hypothermia holds promise in the neuroprotective therapy in the likelihood of such events.

The above mechanisms can, similarly, help play a role in the post-resuscitative management in babies with sudden unexpected postnatal collapse or SIDS. As with HIE (hypoxic-ischemic encephalopathy), therapeutic hypothermia, if initiated within the first few hours of the event, can help improve neurologic outcomes, as in our patient.

Conclusion

To our knowledge, this is the first case report of a late preterm neonate associated with moderate encephalopathy secondary to postnatal cardiac arrest successfully treated with therapeutic hypothermia and had normal long neurodevelopment outcome.

References

- 1 Bernard SA, Gray TW, Buist MD (2002) Treatment of comatose survivors of out-of-hospital cardiac arrest with induced hypothermia. *N Engl J Med* 346: 557-563.
- 2 Moler FW, Silverstein FS (2015) Therapeutic hypothermia after out-of-hospital cardiac arrest in children. *N Engl J Med* 372: 1898-1908.
- 3 Fink EL, Clark RS, Kochanek PM (2010) A tertiary care center's experience with therapeutic hypothermia after pediatric cardiac arrest. *Pediatr Crit Care Med*. 11: 66-74.
- 4 Poets A, Steinfeldt R, Poets CF (2011) Sudden deaths and severe apparent life-threatening events in term infants within 24 h of birth. *Pediatrics*. 127: e869-873.
- 5 Herlenius E, Kuhn P (2013) Sudden unexpected postnatal collapse of newborn infants: A review of cases, definitions, risks and preventive measures. *Translational Stroke Research* 4: 236-247.
- 6 Weber MA, Ashworth MT, Risdon RA, Brooke I, Malone M, et al. (2009) Sudden unexpected neonatal death in the first week of life: autopsy findings from a specialist centre. *J Matern Fetal Neonatal Med*. 22: 398-404.
- 7 Poets A, Urschitz MS, Steinfeldt R, Poets CF (2012) Risk factors for early sudden deaths and severe apparent life threatening events. *Arch Dis Child Fetal Neonatal Ed* 97: F395-397.
- 8 Bernard SA, Gray TW, Buist MD (2002) Treatment of comatose survivors of out-of-hospital cardiac arrest with induced hypothermia. *N Engl J Med* 346: 557-563.
- 9 Hypothermia after Cardiac Arrest Study Group (2002) Mild therapeutic hypothermia to improve the neurologic outcome after cardiac arrest, [erratum appears in *N Engl J Med* 346: 1756.
- 10 Corry JJ, Dhar R, Murphy T, Diringner MN (2008) Hypothermia for refractory status epilepticus. *Neurocrit Care* 9: 189-197.
- 11 Bennett AE, Hoesch RE (2014) Therapeutic Hypothermia in status epilepticus: A report, historical perspective, and review. *Clinical Neurology and Neurosurgery* 126: 103-109.
- 12 Kochanek PM, Fink EL (2009) Therapeutic hypothermia: Applications in pediatric cardiac arrest. *J of Neurotrauma*. 26: 421-427.
- 13 Edwards AD, Yue X, Squier MV (1995) Specific inhibition of apoptosis after cerebral hypoxia-ischaemia by moderate post-insult hypothermia. *Biochem Biophys Res Commun*. 217: 1193-1199.
- 14 Rothstein RP, Levison SW (2005) Gray matter oligodendrocyte progenitors and neurons die caspase-3 mediated deaths subsequent to mild perinatal hypoxic/ischemic insults. *Dev Neurosci*. 27: 149-159.
- 15 Sahuquillo J, Vilalta A (2007) Cooling the injured brain: how does moderate hypothermia influence the pathophysiology of traumatic brain injury. *Curr Pharm Des*. 13: 2310-2322.
- 16 Azzopardi D, Brocklehurst P, Edwards D (2008) The TOBY Study. Whole body hypothermia for the treatment of perinatal asphyxial encephalopathy: a randomised controlled trial. *BMC Pediatr*. 8: 17.
- 17 Amess PN, Penrice J, Cady EB, Lorek A, Wylezinska M, et al. (1997) Mild hypothermia after severe transient hypoxia-ischemia reduces the delayed rise in cerebral lactate in the newborn piglet. *Pediatr Res*. 41: 803-808.